

The Skeletal System**CHAPTER****5***The Skeletal System*

The skeleton is constructed of two of the most supportive tissues found in the human body—cartilage and bone. Besides supporting and protecting the body as an internal framework, the skeleton provides a system of levers that the skeletal muscles use to move the body. In addition, the bones provide a storage depot for substances such as lipids and calcium, and blood cell formation goes on within their red marrow cavities.

The skeleton consists of bones connected at joints, or articulations, and is subdivided into two divisions. The axial skeleton includes those bones that lie around the body's center of gravity. The appendicular skeleton includes the bones of the limbs.

Topics for student review include structure and function of long bones, location and naming of specific bones in the skeleton, fracture types, and a classification of joint types in the body.

BONES—AN OVERVIEW

1. Classify each of the following terms as a projection (*P*) or a depression or opening (*D*). Enter the appropriate letter in the answer blanks.

- | | | |
|----------------|----------------|-------------------|
| ___ 1. Condyle | ___ 4. Foramen | ___ 7. Ramus |
| ___ 2. Crest | ___ 5. Head | ___ 8. Spine |
| ___ 3. Fissure | ___ 6. Meatus | ___ 9. Tuberosity |

2. Group each of the following bones into one of the four major bone categories. Use *L* for long bone, *S* for short bone, *F* for flat bone, and *I* for irregular bone. Enter the appropriate letter in the space provided.

- | | | |
|------------------|-------------------|-----------------|
| ___ 1. Calcaneus | ___ 4. Humerus | ___ 7. Radius |
| ___ 2. Frontal | ___ 5. Mandible | ___ 8. Sternum |
| ___ 3. Femur | ___ 6. Metacarpal | ___ 9. Vertebra |

3. Using the key choices, characterize the following statements relating to long bones. Enter the appropriate term(s) or letter(s) in the answer blanks.

Key Choices

- | | | |
|---------------------|---------------|-------------------------|
| A. Diaphysis | C. Epiphysis | E. Yellow marrow cavity |
| B. Epiphyseal plate | D. Red marrow | |

- _____ 1. Site of spongy bone in the adult
- _____ 2. Site of compact bone in the adult
- _____ 3. Site of hematopoiesis in the adult
- _____ 4. Scientific name for bone shaft
- _____ 5. Site of fat storage in the adult
- _____ 6. Site of longitudinal growth in a child

4. Complete the following statements concerning bone formation and destruction, using the terms provided in the key. Insert the key letter or corresponding term in the answer blanks.

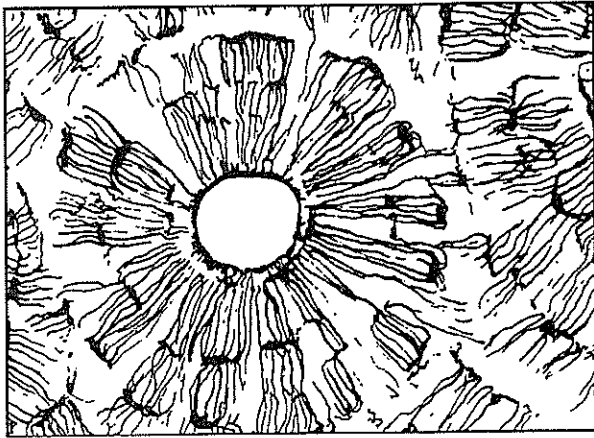
Key Choices

- | | | | |
|---------------|----------------|----------------|--------------------------|
| A. Atrophy | C. Gravity | E. Osteoclasts | G. Parathyroid hormone |
| B. Calcitonin | D. Osteoblasts | F. Osteocytes | H. Stress and/or tension |

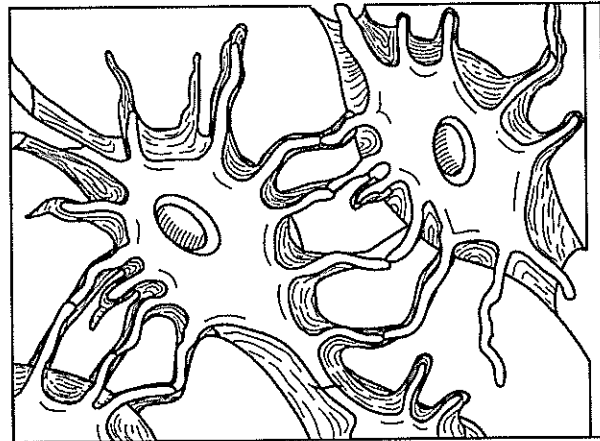
- _____ 1. When blood calcium levels begin to drop below homeostatic levels, (1) is released, causing calcium to be released from bones.
- _____ 2. Mature bone cells, called (2), maintain bone in a viable state.
- _____ 3. Disuse such as that caused by paralysis or severe lack of exercise results in muscle and bone (3).
- _____ 4. Large tubercles and/or increased deposit of bony matrix occur at sites of (4).
- _____ 5. Immature, or matrix-depositing, bone cells are referred to as (5).
- _____ 6. (6) causes blood calcium to be deposited in bones as calcium salts.
- _____ 7. Bone cells that liquefy bone matrix and release calcium to the blood are called (7).
- _____ 8. Our astronauts must do isometric exercises when in space because bones atrophy under conditions of weightlessness or lack of (8).

5. Five descriptions of bone structure are provided in Column A. First identify the structure by choosing the appropriate term from Column B and placing the corresponding answer in the answer blank. Then consider Figure 5-1A, a diagrammatic view of a cross section of bone, and 5-1B, a higher magnified view of compact bone tissue. Select different colors for the structures and bone areas in Column B, and use them to color the coding circles and corresponding structures on the figure diagrams. Since the concentric lamellae would be difficult to color without confusing other elements, identify one lamella by using a bracket and label.

Column A	Column B
_____ 1. Layers of calcified matrix	A. Central (Haversian) canal <input type="radio"/>
_____ 2. "Residences" of osteocytes	B. Concentric lamellae
_____ 3. Longitudinal canal, carrying blood vessels and nerves	C. Lacunae <input type="radio"/>
_____ 4. Nonliving, structural part of bone	D. Canaliculi <input type="radio"/>
_____ 5. Tiny canals, connecting lacunae	E. Bone matrix <input type="radio"/>
	F. Osteocyte <input type="radio"/>



A



B

Figure 5-1

6. Circle the term that does not belong in each of the following groupings.

- | | | | |
|----------------------|---------------------|---------------|-------------------|
| 1. Hematopoiesis | Red marrow | Yellow marrow | Spongy bone |
| 2. Lamellae | Canaliculi | Circulation | Osteoblasts |
| 3. Osteon | Marrow cavity | Central canal | Canaliculi |
| 4. Epiphysis surface | Articular cartilage | Periosteum | Hyaline cartilage |

- _____ 1. Forehead bone
- _____ 2. Cheekbone
- _____ 3. Lower jaw
- _____ 4. Bridge of nose
- _____ 5. Posterior part of hard palate
- _____ 6. Much of the lateral and superior cranium
- _____ 7. Most posterior part of cranium
- _____ 8. Single, irregular, bat-shaped bone, forming part
of the cranial floor
- _____ 9. Tiny bones, bearing tear ducts
- _____ 10. Anterior part of hard palate
- _____ 11. Superior and middle nasal conchae formed
from its projections
- _____ 12. Site of mastoid process
- _____ 13. Site of sella turcica
- _____ 14. Site of cribriform plate
- _____ 15. Site of mental foramen
- _____ 16. Site of styloid process
- _____ 17. _____ 18. Four bones, containing
paranasal sinuses
- _____ 19. _____ 20.
- _____ 21. Its condyles articulate with the atlas
- _____ 22. Foramen magnum contained here
- _____ 23. Middle ear found here
- _____ 24. Nasal septum
- _____ 25. Bears an upward protrusion, the "cock's comb," or crista galli

9. Figure 5-3, A-C shows lateral, anterior, and inferior views of the skull. Select different colors for the bones listed below and color the coding circles and corresponding bones in the figure. Complete the figure by labeling the bone markings indicated by leader lines.

- | | | | |
|--------------------------------|--------------------------------|---------------------------------|--------------------------------|
| <input type="radio"/> Frontal | <input type="radio"/> Sphenoid | <input type="radio"/> Zygomatic | <input type="radio"/> Nasal |
| <input type="radio"/> Parietal | <input type="radio"/> Ethmoid | <input type="radio"/> Palatine | <input type="radio"/> Lacrimal |
| <input type="radio"/> Mandible | <input type="radio"/> Temporal | <input type="radio"/> Occipital | <input type="radio"/> Vomer |
| <input type="radio"/> Maxilla | | | |

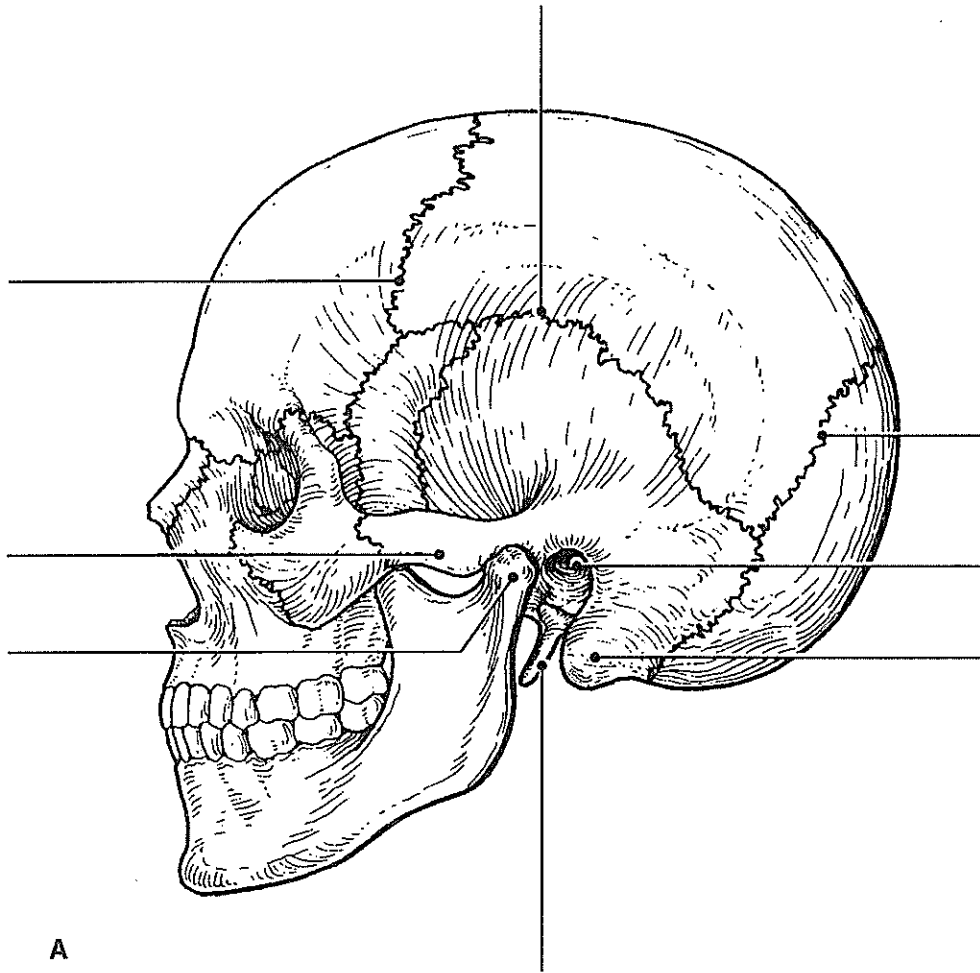
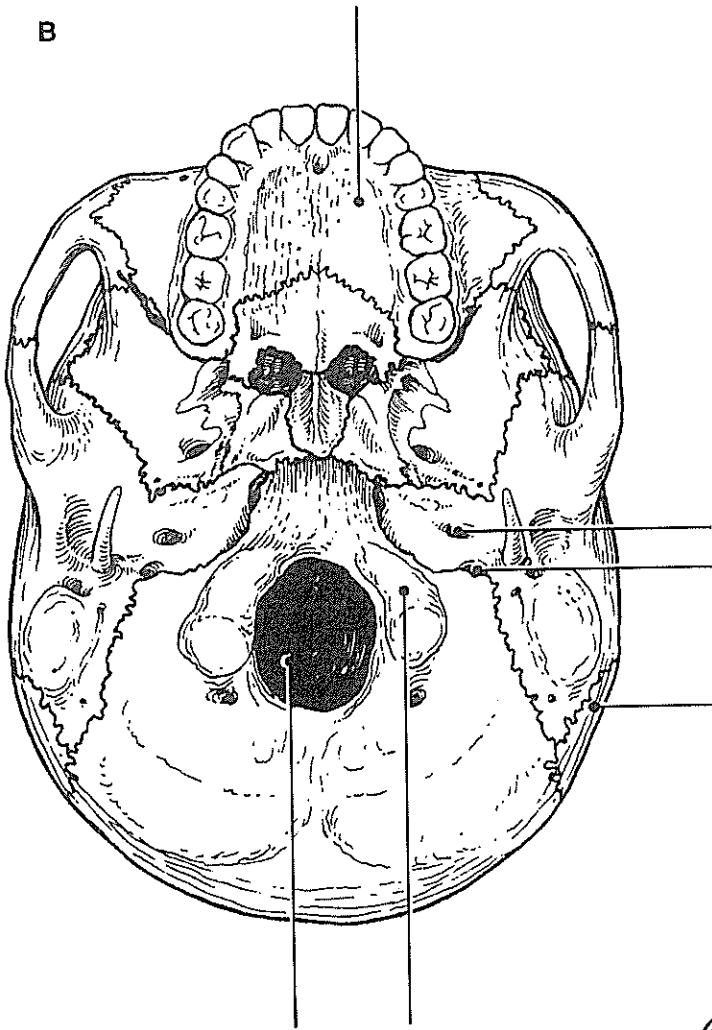
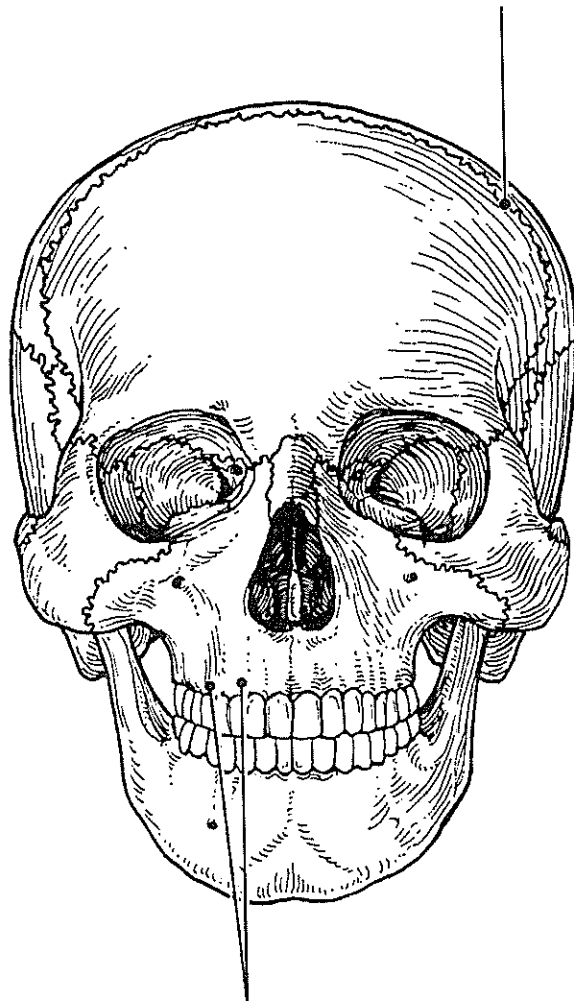


Figure 5-3, A-C

B



C



10. An anterior view of the skull, showing the positions of the sinuses, is provided in Figure 5-4. First select different colors for each of the sinuses and use them to color the coding circles and the corresponding structures on the figure. Then briefly answer the following questions concerning the sinuses.

1. What *are* sinuses? _____

2. What purpose do they serve in the skull? _____

3. Why are they so susceptible to infection? _____

Sphenoid sinus

Ethmoid sinuses

Frontal sinus

Maxillary sinus

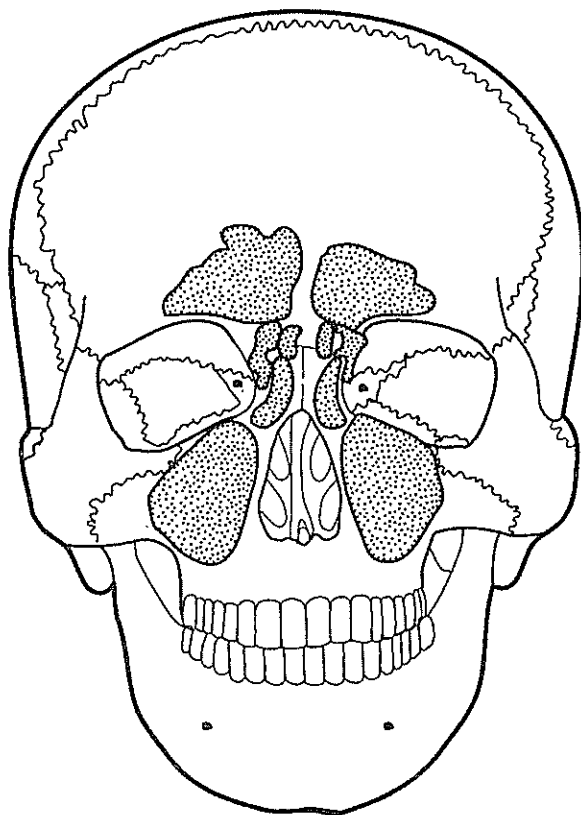


Figure 5-4

Vertebral Column

11. Using the key choices, correctly identify the vertebral parts/areas described as follows. Enter the appropriate term(s) or letter(s) in the spaces provided.

Key Choices

- | | | |
|----------------------------|-------------------------------|-----------------------|
| A. Body | C. Spinous process | E. Transverse process |
| B. Intervertebral foramina | D. Superior articular process | F. Vertebral arch |

- _____ 1. Structure that encloses the nerve cord
- _____ 2. Weight-bearing portion of the vertebra
- _____ 3. Provide(s) levers for the muscles to pull against
- _____ 4. Provide(s) an articulation point for the ribs
- _____ 5. Openings providing for exit of spinal nerves

12. The following statements provide distinguishing characteristics of the vertebrae composing the vertebral column. Using key choices, identify each described structure or region by inserting the appropriate term(s) or letter(s) in the spaces provided.

Key Choices

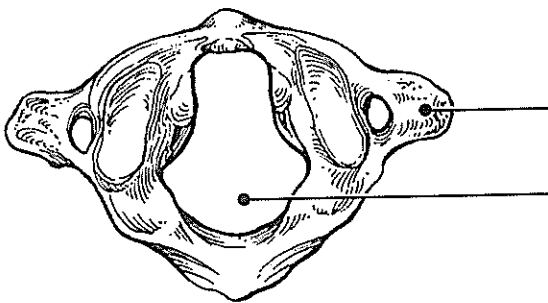
- | | | |
|----------|--------------------|----------------------|
| A. Atlas | D. Coccyx | F. Sacrum |
| B. Axis | E. Lumbar vertebra | G. Thoracic vertebra |
- C. Cervical vertebra—typical

- _____ 1. Type of vertebra(e) containing foramina in the transverse processes, through which the vertebral arteries ascend to reach the brain
- _____ 2. Its dens provides a pivot for rotation of the first cervical vertebra
- _____ 3. Transverse processes have facets for articulation with ribs; spinous process points sharply downward
- _____ 4. Composite bone; articulates with the hip bone laterally
- _____ 5. Massive vertebrae; weight-sustaining
- _____ 6. Tailbone; vestigial fused vertebrae
- _____ 7. Supports the head; allows the rocking motion of the occipital condyles
- _____ 8. Seven components; unfused
- _____ 9. Twelve components; unfused

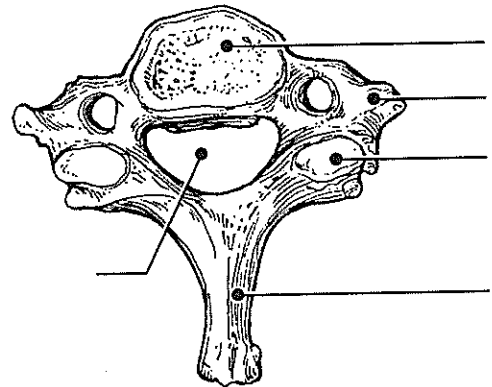
13. Complete the following statements by inserting your answers in the answer blanks.

- _____ 1. In describing abnormal curvatures, it could be said that (1) is an exaggerated thoracic curvature, and in (2) the vertebral column is displaced laterally.
- _____ 2.
- _____ 3. Intervertebral discs are made of (3) tissue. The discs provide (4) to the spinal column.
- _____ 4.

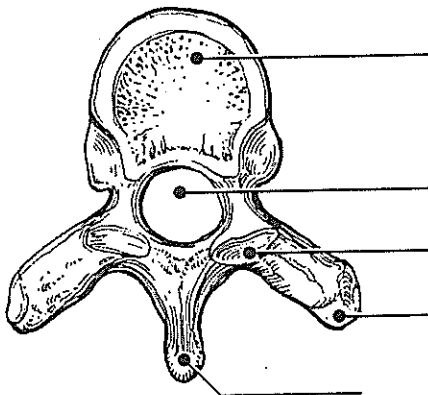
14. Figure 5-5, A-D shows superior views of four types of vertebrae. In the spaces provided below each vertebra, indicate in which region of the spinal column it would be found. In addition, specifically identify Figure 5-5A. Where indicated by leader lines, identify the vertebral body, spinous and transverse processes, superior articular processes, and vertebral foramen.



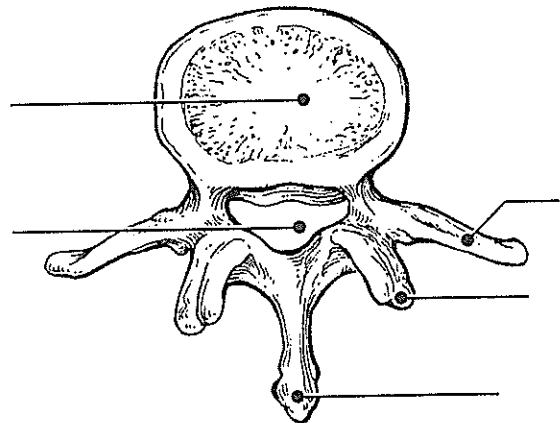
A _____



B _____



C _____

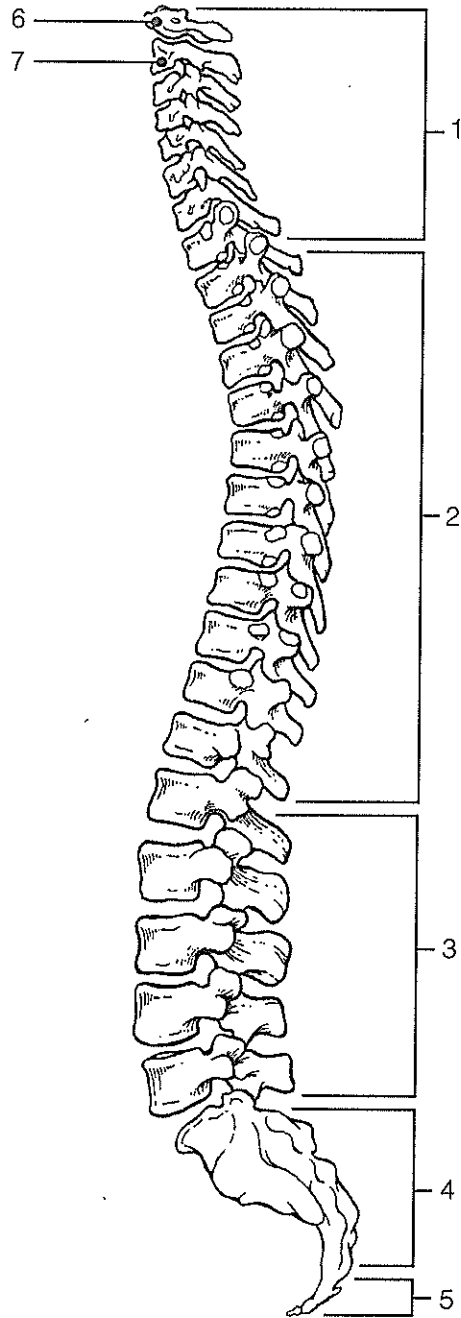


D _____

Figure 5-5

15. Figure 5-6 is a lateral view of the vertebral column. Identify each numbered region of the column by listing in the numbered answer blanks the region name first and then the specific vertebrae involved (for example, sacral region, S# to S#). Also identify the modified vertebrae indicated by numbers 6 and 7 in Figure 5-6. Select different colors for each vertebral region and use them to color the coding circles and the corresponding regions.

- 1. _____ ○
- 2. _____ ○
- 3. _____ ○
- 4. _____ ○
- 5. _____ ○
- 6. _____ ○
- 7. _____ ○



 **Figure 5-6**

Bony Thorax

16. Complete the following statements referring to the bony thorax by inserting your responses in the answer blanks.

- _____ 1. The organs protected by the thoracic cage include the (1)
 _____ 2. and the (2). Ribs 1 through 7 are called (3) ribs,
 _____ 3. whereas ribs 8 through 12 are called (4) ribs. Ribs 11 and
 _____ 4. 12 are also called (5) ribs. All ribs articulate posteriorly
 _____ 5. with the (6), and most connect anteriorly to the (7),
 _____ 6. either directly or indirectly.
 _____ 7. The general shape of the thoracic cage is (8).
 _____ 8.

17. Figure 5-7 is an anterior view of the bony thorax. Select different colors to identify the structures below and color the coding circles and corresponding structures. Then label the subdivisions of the sternum indicated by leader lines.

- | | |
|---|--------------------------------------|
| <input type="radio"/> All true ribs | <input type="radio"/> All false ribs |
| <input type="radio"/> Costal cartilages | <input type="radio"/> Sternum |

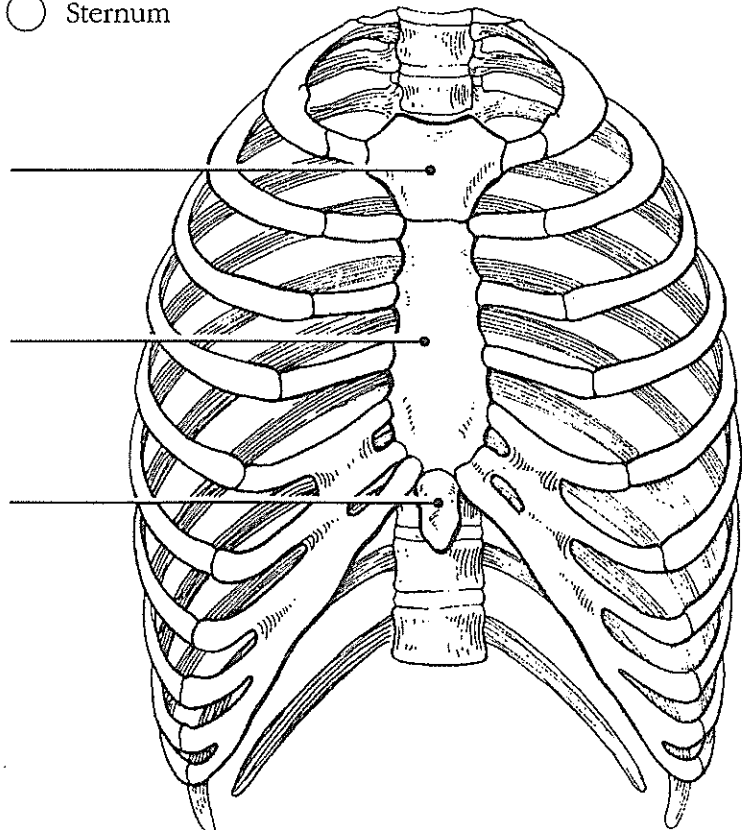


Figure 5-7